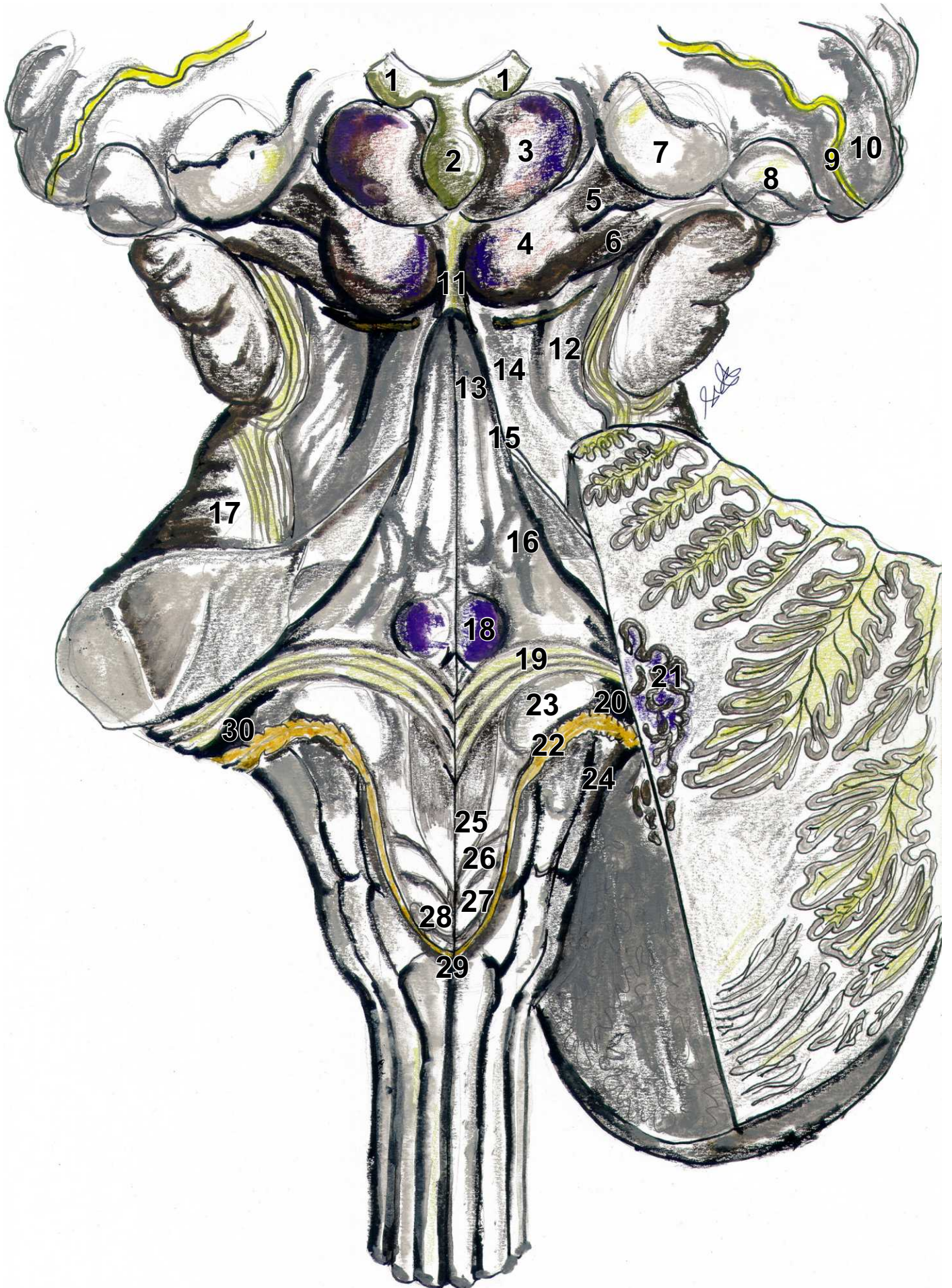


Fossa rhomboidea



Fossa rhomboidea

1. Habenula
2. Corpus pineale
3. Colliculus superior
4. Colliculus inferior
5. Brachium coll. sup.
6. Brachium coll. inf.
7. Corpus geniculatum mediale
8. Corpus geniculatum laterale
9. Stria terminalis
10. Pulvinar thalami
11. Frenulum veli medullaris sup.
12. Trigonum lemnisci + Sulcus lat mesencephali
13. Eminentia medialis + Sulcus med. fossae rhomboideae
14. Pedunculus cerebellaris sup. (Brachium conjunctivum)
15. Eminentia lat.
16. Locus coeruleus
17. Pedunculus cerebellaris med. (Brachium pontis)
18. Colliculus facialis
19. Striae medullares
20. Apertura lateralis ventriculi quartii (Luschka)
21. Nucleus dentatus
22. Taenia choroidea ventriculi quartii
23. Area vestibularis
24. Pedunculus cerebellaris inf.
25. Trigonum nervi XII.
26. Trigonum nervi X.
27. Fasciculus separans + area postrema
28. Calamus scriptorius
29. Obex
30. Recessus lateralis ventriculi quartii