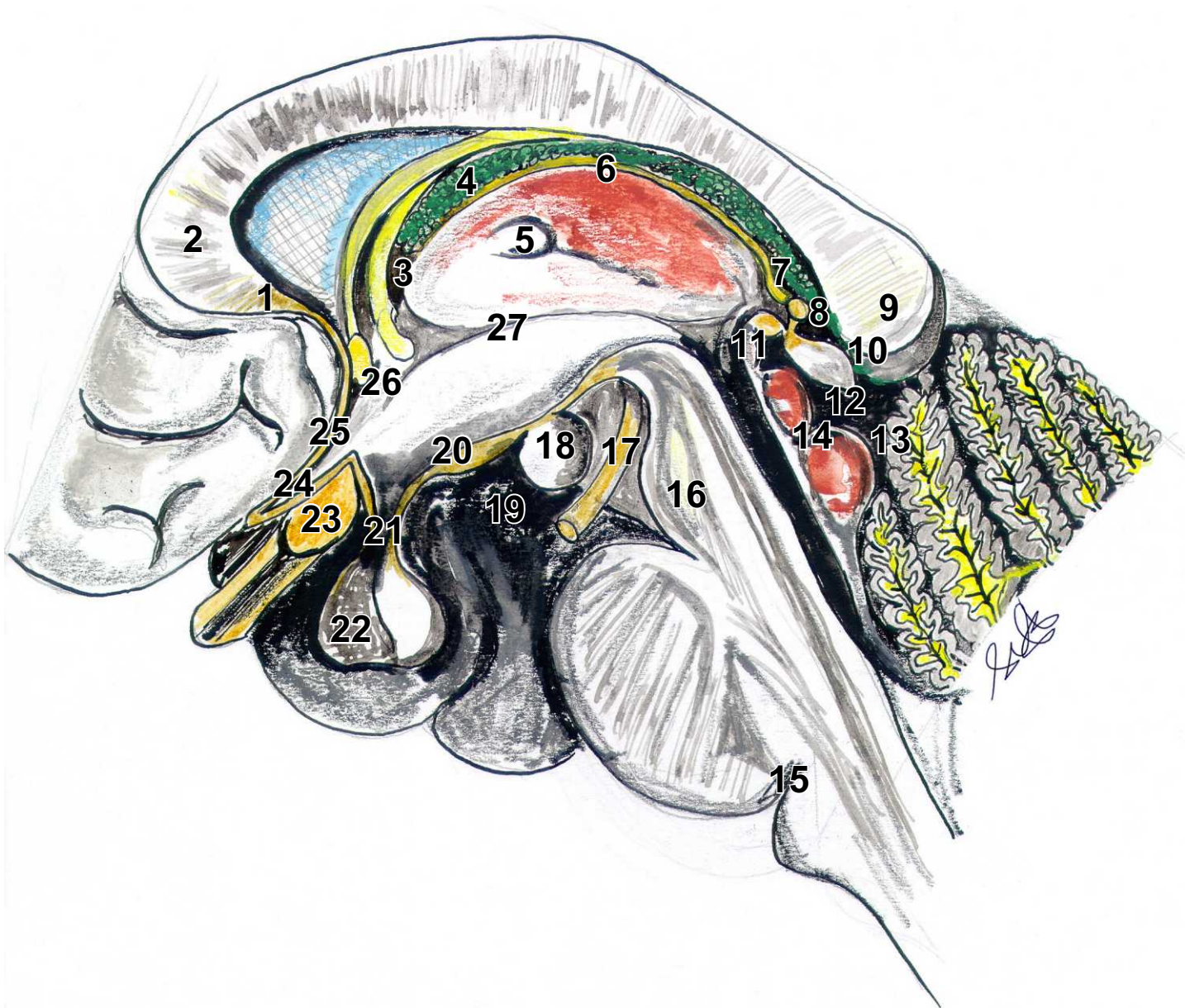


Ventriculus terlius



Ventriculus tertius

1. Rostrum corporis callosi
2. Genu corporis callosi
3. Foramen interventriculare (Monroi)
4. Plexus choroideus ventr. tertii
5. Adhesio interthalamica
6. Stria medullaris thalami
7. Recessus pinealis
8. Recessus suprapinealis
9. Splenium
10. Velum interpositum
11. Commissura posterior
12. Corpus pineale
13. Cisterna venae magna (Galenii)
14. Vierhügelplatte
15. Foramen caecum
16. Crus cerebri
17. N. oculomotorius (III)
18. Corpus mamillare
19. Substantia perforata post.
20. Tuber cinereum
21. Recessus infundibuli
22. Adenohypophyse
23. Chiasma opticum
24. Recessus opticus
25. Lamina terminalis
26. Commissura anterior
27. Sulcus hypothalamicus